

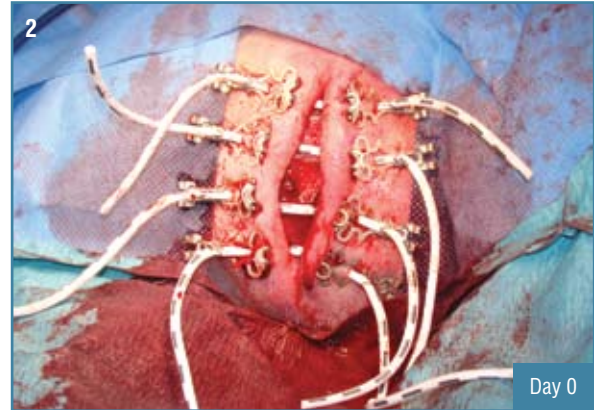
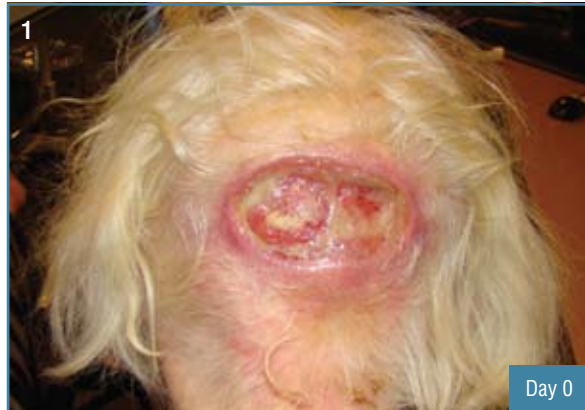Head ulcer

History

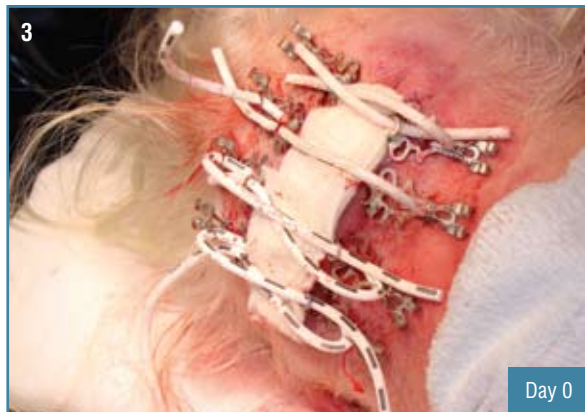A 91-year-old woman was admitted to hospital with an ulcer on the back of her head caused by a rigid neck collar treating a comminuted cervical fracture. The wound measured 6 x 4cm and was deep enough to expose bone. The wound was primarily treated with liver oil ointment and after one week the exposed bone in the wound bed had covered. The surgeons chose the ABRA Surgical Skin Closure System due to the difficulties in closing the wound.

Post note from attending clinician: "At the end of the treatment an added bonus which pleased the elderly lady very much was a face lift for free."

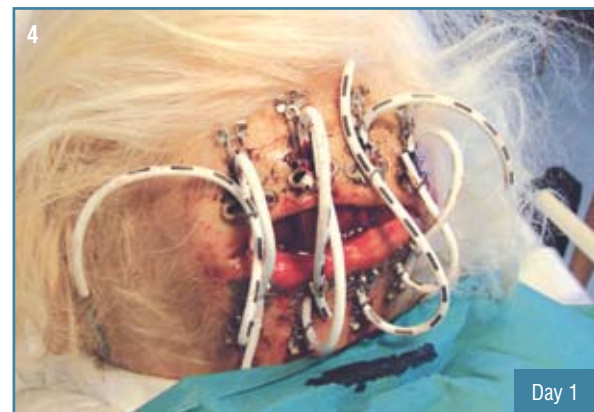
Case study courtesy of Dr. Steffen Skov and Nurse Louise Hosbond, Viborg Hospital, Viborg, Denmark.



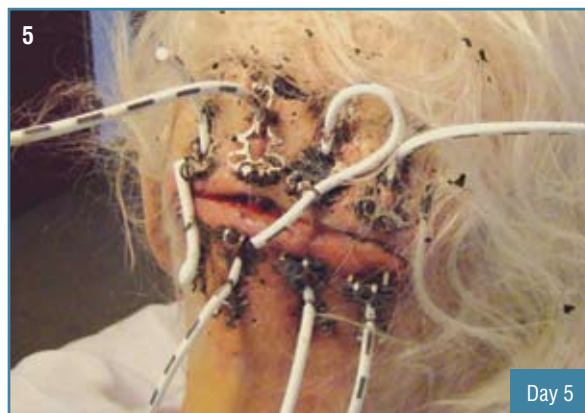ABRA Surgical Skin Closure system installed.



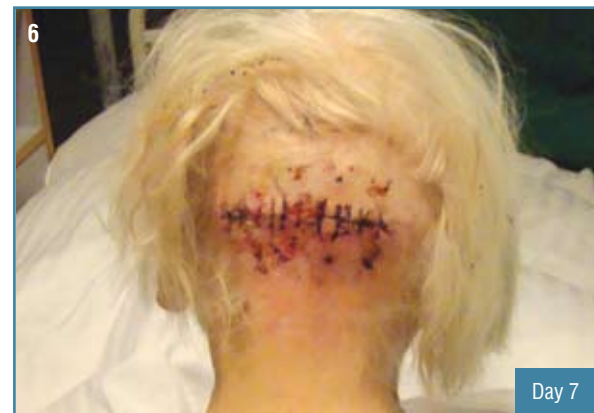Wound covered with dressing.



Tensioning.



Wound edges approximated. Closure by sutures achieved on day 6.



One day after suturing.