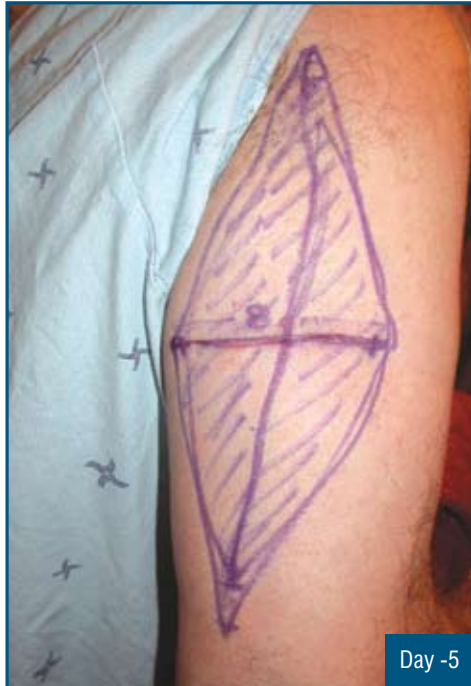


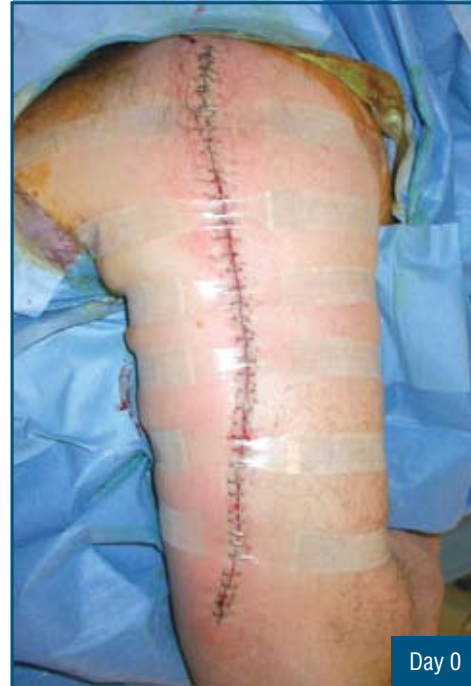Topical Pre-operative Skin Expansion on Arm

History

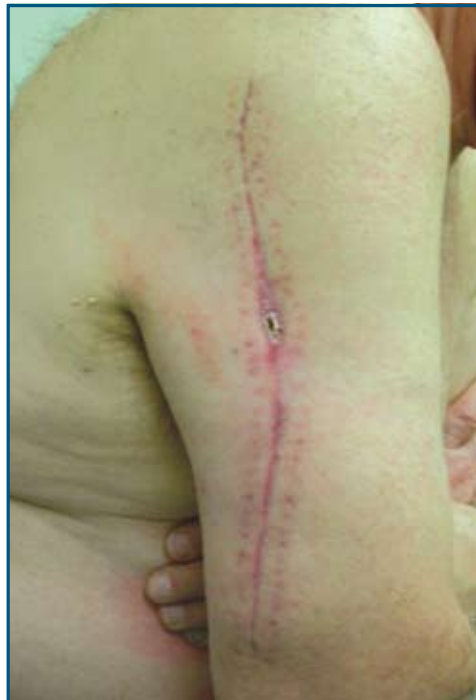Incomplete prior excision and horizontal orientation of initial incision led to requirement of this extensive vertical re-excision.



Large removal area. Five days of pre-operative DynaClose skin expansion.



Closed primarily. DynaClose applied to relieve suture tension and prevent dehiscence.



Healing well.