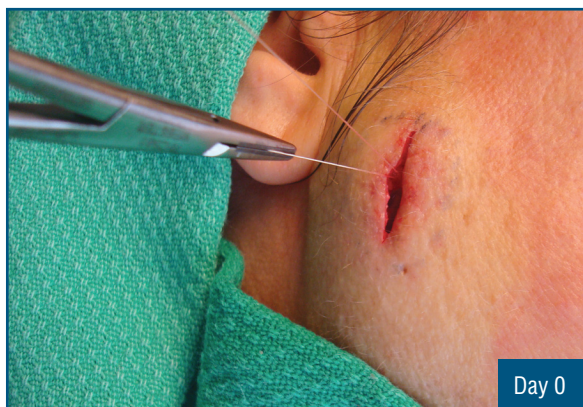

## Removal of Epidermal Inclusion Cyst

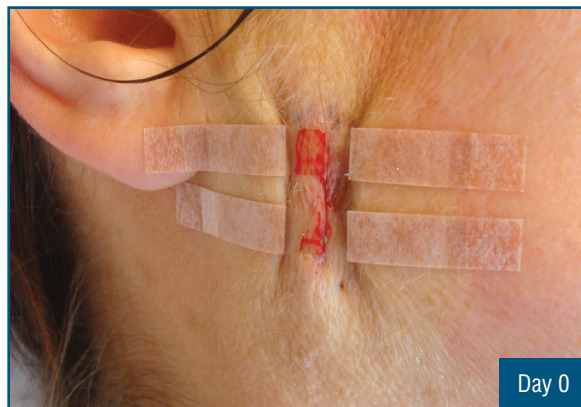
### History

A routine in-office procedure for a forty-five-year-old female to remove an epidermal inclusion cyst at the right facial cheek region. Following the removal of the cyst, dissolvable sutures were used to reapproximate the underlying fascia and dermal edges, then skin edges were reapproximated using DynaClose. DynaClose was reapplied at home by the patient approximately every other day for seven days.

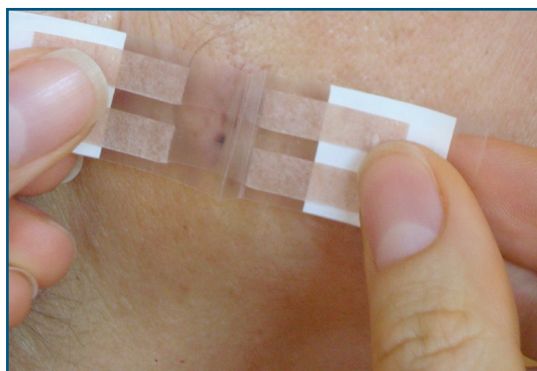
*Case study courtesy of Dr. Jeffrey Abboud - Plastic Surgeon, Ottawa, Ontario, Canada.*



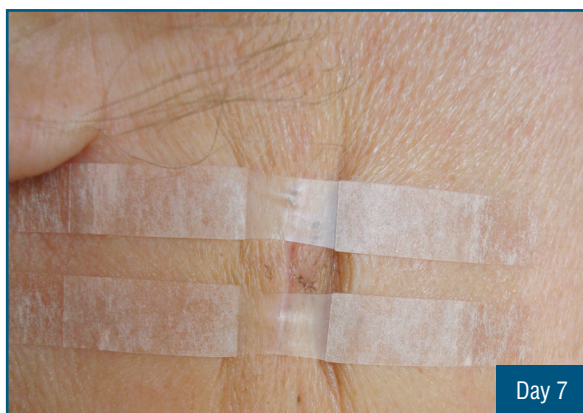
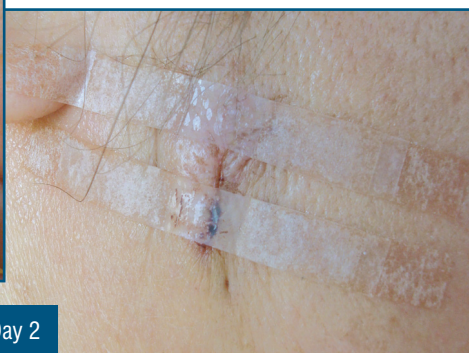Suturing of underlying fascia.



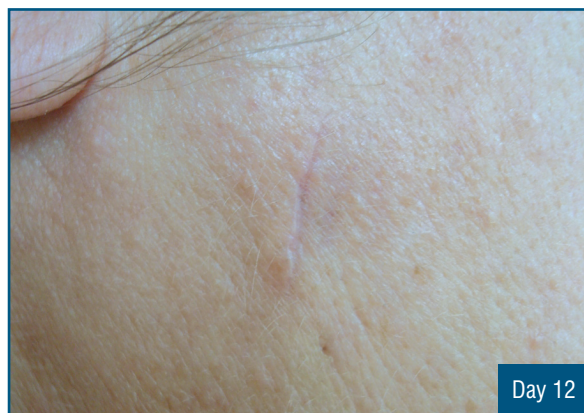DynaClose applied to reapproximate skin edges.



Applying DynaClose at home.



Final DynaClose application one week after procedure.



Good cosmetic results less than two weeks after procedure.