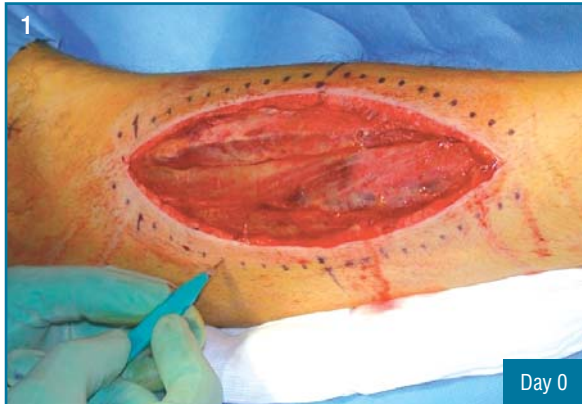

Fasciotomy Closure

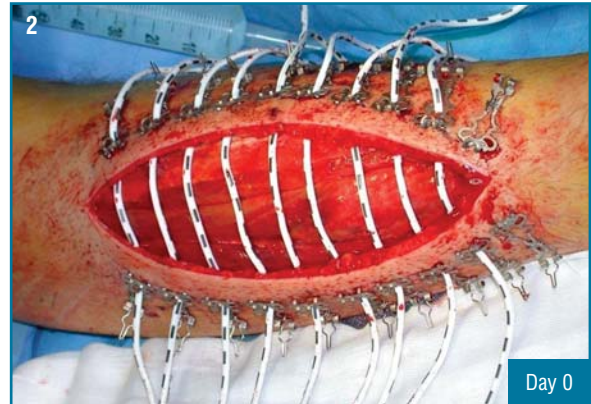
History

A fifteen-year-old male gymnast was hospitalized with complicated fracture of the tibia. Twenty-four hours after bone fixation, he developed acute compartment syndrome. The ABRA Surgical Skin Closure System was installed one day after the resulting fasciotomy.

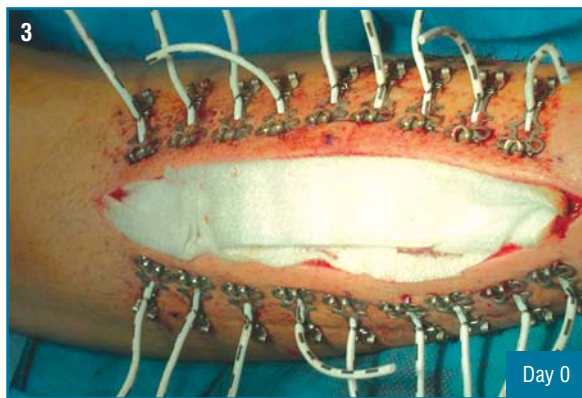
Case study courtesy of Dr. Steffen Skov, Viborg Sygehus, Viborg, Denmark.



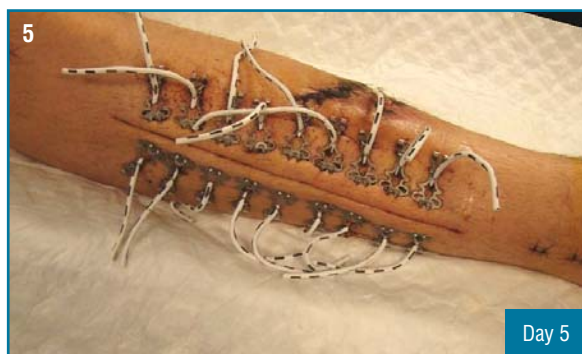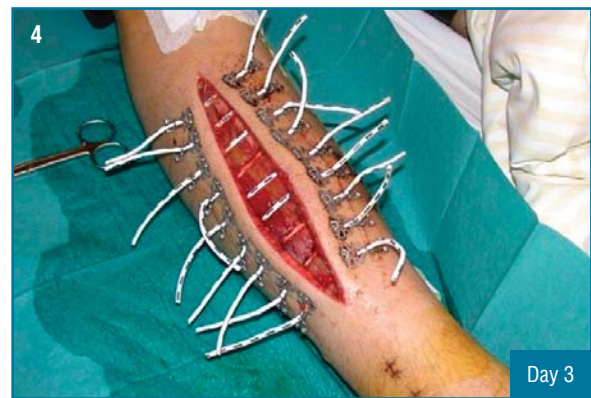Layout.



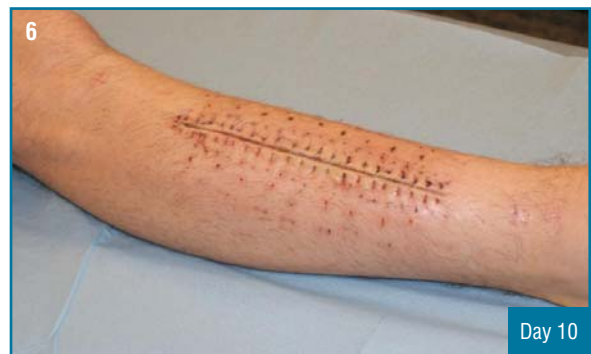Before elastomer tensioning.



After tensioning and dressing.



Wound edges approximated. Closure by sutures achieved on Day 5.



Sutures removed on Day 10.