

## Full Thickness Abdominal Wall Closure with ABRA® and EZCARE™ NPWT

**Day of Injury** - This previously healthy twenty-nine-year-old woman was hit by a high-speed motorcycle which caused her to be projected into an oncoming car. She sustained mild head trauma, severe thoracic, abdominal and pelvic trauma with massive bleeding, as well as moderate right lower limb trauma. The surgical team placed a left chest tube and advanced to a formal laparotomy to perform a splenectomy, left nephrectomy, abdominal and pelvic packing. In a desperate move for haemostasis her fascia and skin were closed over the preformed packing.

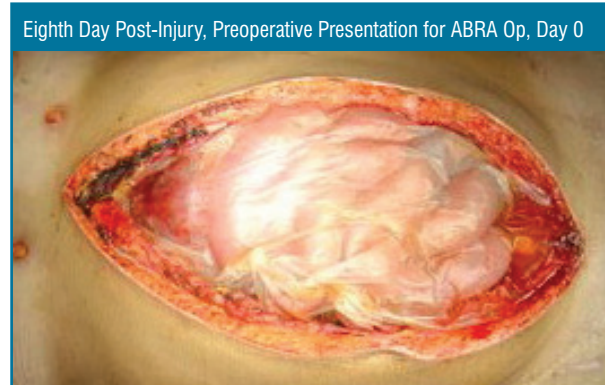
**Second Day Post-Injury** - She suffered progressive deterioration of her respiratory and urinary systems attributed to abdominal compartment syndrome. The surgical team decompressed her abdomen, made a limited exploration of the bowel because her haemostasis was unsatisfactory, requested more blood and FFP, placed more packs in paracolic gutters and pelvis and made a temporary abdominal closure with a sandwich technique under negative pressure.

**Fifth Day Post-Injury** - Severe edema, minor bleeding and gallbladder ischemia was diagnosed. Bleeding was controlled with a few ligations and sutures.

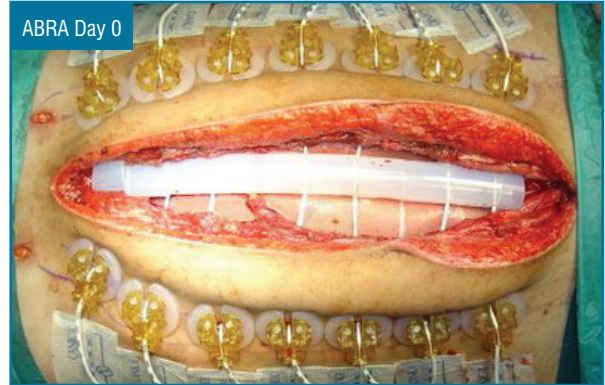
**Eighth Day Post-Injury (ABRA Op, Day 0)** - Acute cholecystitis and retroperitoneal edema was diagnosed. A cholecystectomy was performed and ABRA was applied with EZCARE™ NPWT.

*Case study courtesy of Dr. Fernando Ferreira, Surgery, Hospital Pedro Hispano, Matosinhos, Portugal.*

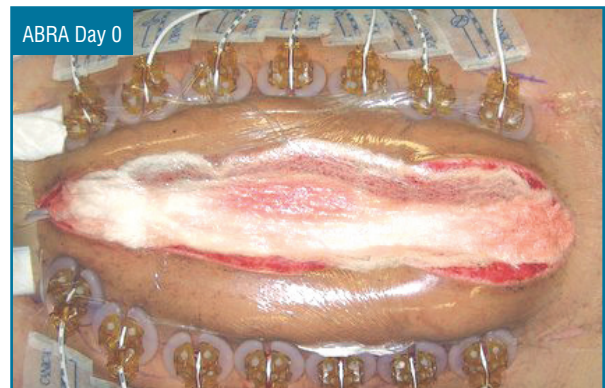EZCARE™ is a trademark of Smith & Nephew



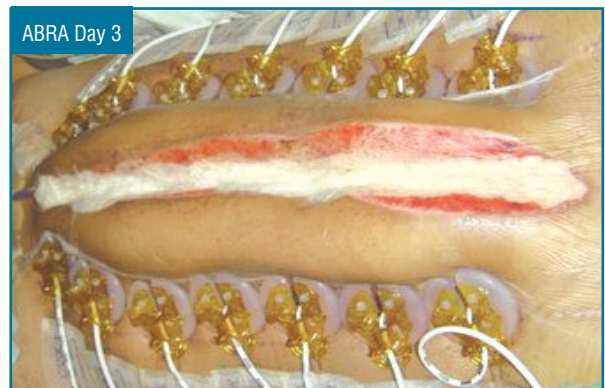Beginning of ABRA application surgery.



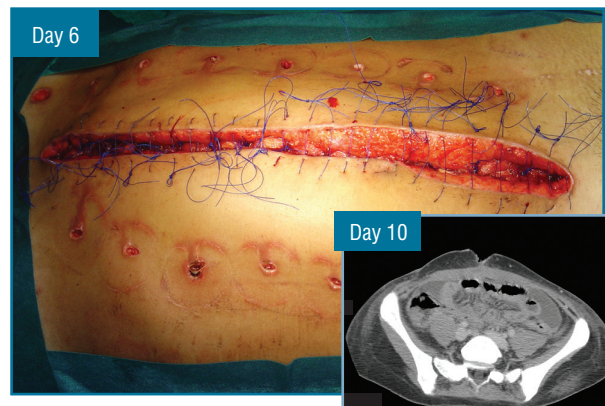
Aspect after "The Move" (palmar compression of abdominal wall - see IFU\*).



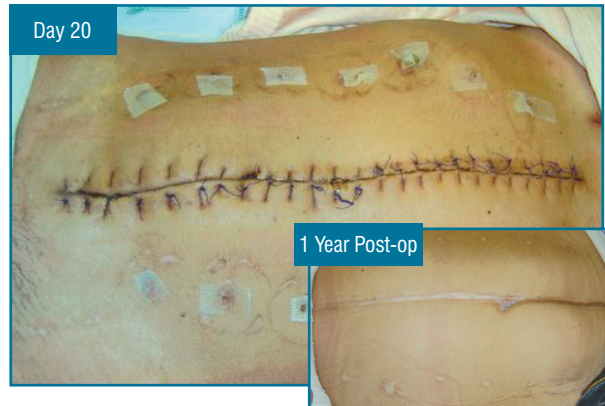After EZCARE™ vacuum application, on return to ICU.



ABRA Day 3 after replacement of EZCARE™ dressings and repeating "The Move".



ABRA removed and fascia closed with little tension, skin left open for deferred closure. On Day 10, fascia closure was verified by CT scan.



Skin was closed on **Day 16** after resolution of the wound infection. The patient was discharged on Day 25, 33 days after the accident with no hernia and no mesh.