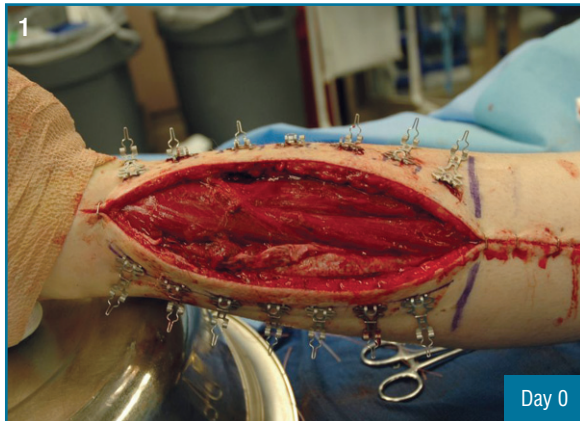

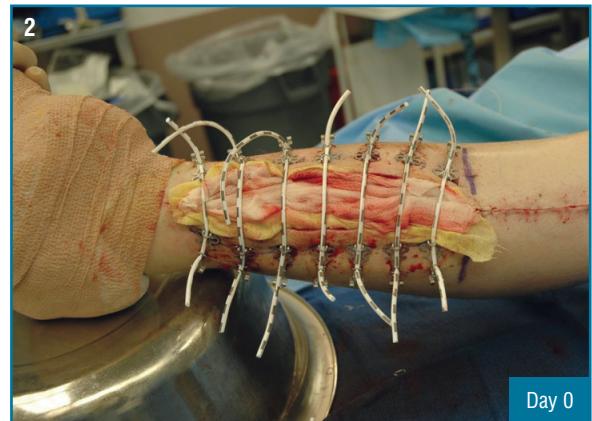
## Fasciotomy Closure

### History

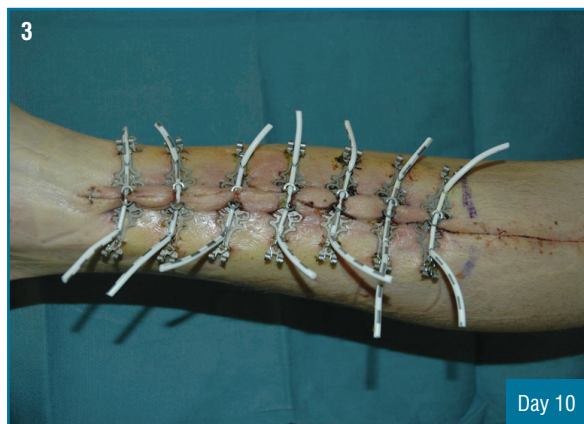
A twenty-year-old man involved in a motor vehicle accident, suffered an extremity compartment syndrome which required a bilateral fasciotomy on the left leg. Six days later, the ABRA Surgical Skin Closure System was applied on the lateral incision while the surgeon closed the medial side primarily. The patient was returned to the operating room ten days later where the system was removed and the lateral side was primarily closed.



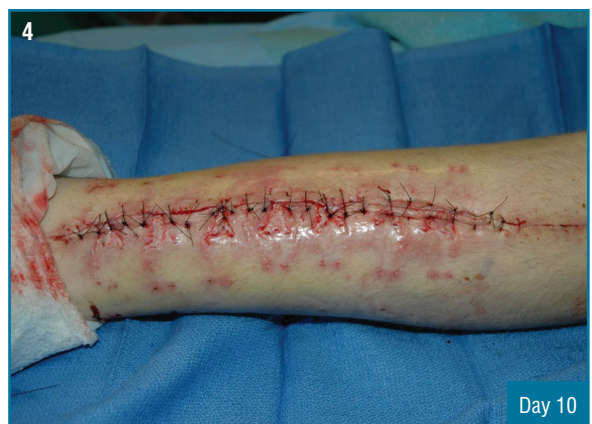Measuring 30 cm x 7.5 cm, six days post bilateral fasciotomy.



ABRA Surgical Skin Closure System as installed.



Ready for closure ten days after installation of the Dynamic Wound Closure System.



Delayed primary closure.