

Sternotomy Closure

History

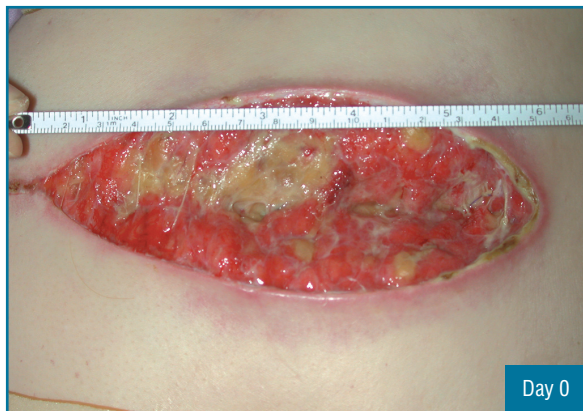This fifty-year-old woman presented with a chronically draining wound (post coronary artery bypass graft). The wound measured 15 cm in length and was retracted to 6 cm.

Treatment

ABRA Adhesive Anchors were applied and the patient was sent home the same day on the advice of the enterostomal-therapist wound-care manager. Home-care nurses managed the wound and adjusted the tension as required.

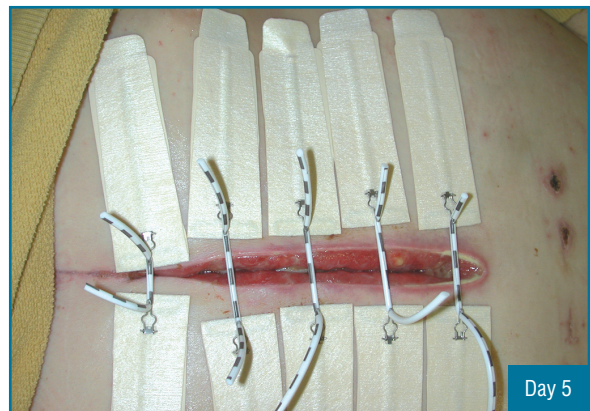
By day five the wound had reduced to 2 cm. Wound edge re-approximation was achieved on day 19. As seen in the photos, the skin under the anchors remained healthy-looking throughout the procedure.

The follow-up photo on day 33 shows the wound margins re-approximated and the wound granulated without the need for suturing.



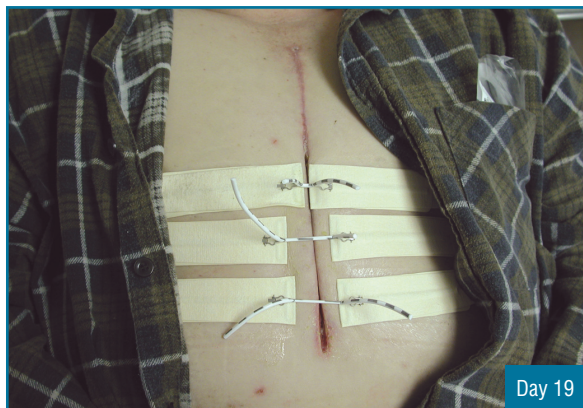
Day 0

As presented, wound measured 15 cm in length, retracted 6 cm.



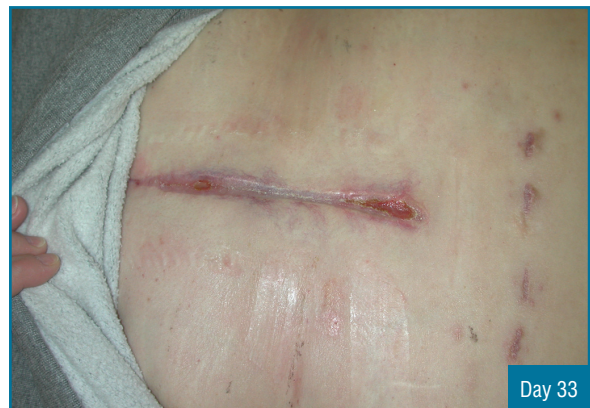Day 5

Wound reduced to 2 cm, five days after installation of the ABRA Adhesive Skin Closure System.



Day 19

Wound edges are re-approximated.



Day 33

Follow-up photo.